

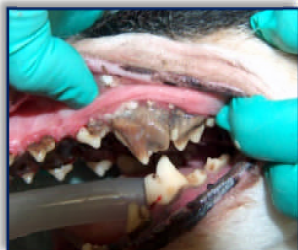


4229 VAN BUREN BOULEVARD, RIVERSIDE, CALIFORNIA 92503
TELEPHONE: 951.689.0440 ~ FACSIMILE: 951.689.4214
EMAIL: INFO@ARLINGTONANIMALHOSPITAL.BIZ
WWW.ARLINGTONANIMALHOSPITAL.BIZ

© ARLINGTON ANIMAL HOSPITAL, INC.

DENTAL DISEASE

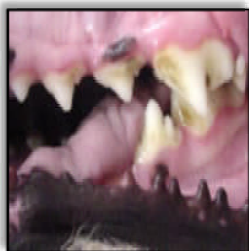
GENERAL INFORMATION ABOUT DENTAL DISEASE



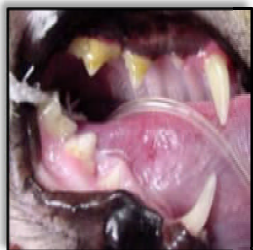Dental disease is one of the most common and overlooked diseases in companion animals. Dental disease occurs because animals cannot brush their teeth. The daily consumption of food results in food particle buildup on and between tooth surfaces. Bacteria in the mouth digest these particles resulting in the formation of plaque, a sticky yellow film coating the tooth surface. As plaque accumulates to significant quantities, bacteria begin to infect the gums causing gingivitis, often seen as a red line along the gums just above the teeth. Over time plaque will harden to form tartar, a matrix of calcium and bacteria. Tartar allows the bacteria to attach to the otherwise smooth tooth surface and helps push it under the gum line promoting cavities, gingivitis and gum recession. Deeper infection of the tooth roots is called periodontal disease, which ultimately results in tooth loss. Dental disease, gingivitis and periodontal disease is just as painful in animals as it is in people.

By three years of age 80% of dogs and 70% of cats show signs of oral disease - The American Veterinary Dental Society (AVDS).

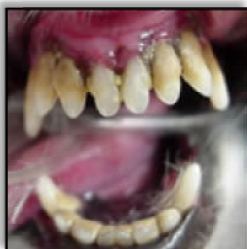
GRADING DENTAL DISEASE



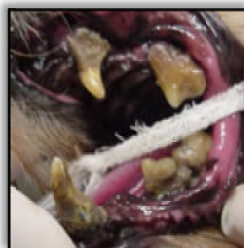
GRADE 1: Tartar has accumulated on the tooth surfaces (crown) but has not reached the gum line. No evidence of gingivitis is present.



GRADE 2: Tartar has accumulated on the crowns and has started to move under the gum line. Evidence of early gingivitis is present.



GRADE 3: Significant tartar has accumulated on the crowns and under the gum line. Significant gingivitis is present with gum recession, periodontal disease and tooth loosening.



GRADE 4: Severe tartar has accumulated on the crowns and under the gum line. Severe gingivitis is present with severe gum recession and periodontal disease. Pus, root exposure and tooth loosening has occurred and teeth can be freely mobile.

SYSTEMIC EFFECTS OF DENTAL DISEASE

Dental disease not only affects teeth and gums, it causes and promotes many other diseases. Teeth and gums have an extensive blood supply that can move harmful dental bacteria throughout the entire body by essentially acting as a highway. Dental disease is a systemic disease that affects the animal's overall health. Some diseases and infections associated with dental disease are:

Heart murmurs	Heart failure	Tonsillitis	Gingivitis (gum loss)
Bronchitis	Pharyngitis (sore throat)	Periodontitis (bony loss)	Respiratory infections
Kidney disease and failure	Liver disease	Facial abscesses	Joint infection and pain
Jaw fractures	Jaw osteoporosis	Sinusitis (Nasal) infections	Pneumonia
Ocular damage/loss	Ocular abscesses	Chronic conjunctivitis	Ear infections/pain

SIGNS OF DENTAL DISEASE

Dental disease is a common and often overlooked disease in dogs and cats. While cavities represent the most common dental problem in humans, tartar accumulation is the most common dental problem in dogs and cats. Signs of dental disease include:

Halitosis (bad breath)	Difficulty eating	Drooling	Chattering of teeth	Temperament changes
Pain when opening the mouth	Oral sensitivity	Chronic tearing	Nasal discharge	Vocalization (crying)

PLEASE TURN OVER

DIETARY EFFECT ON DENTAL DISEASE

Feeding dry food is not an effective method of controlling dental tartar as tartar is very hard and solidly adhered to the tooth surface. Dry food is not as sticky as canned food and thus will be less likely to adhere to the tooth surface and promote dental plaque and tartar. Dental plaque and tartar can accumulate for other reasons such as individual mouth chemistry and immunity, facial and oral structure, teeth crowding and breed predispositions. Dental disease is highly individualized and animals may need a dental cleaning on a routine basis and or may only require a dental cleaning every few years. Routine oral examination and frequent dental cleanings for animals with higher incidence of dental disease will be more economical as this will reduce the overall cost of dental care by minimizing expensive tooth extractions.

DENTAL PROPHYLAXIS (CLEANING)

Dental cleaning requires general anesthesia because it involves multiple steps which can result in a long procedure, may require radiographs (x-rays) to examine tooth roots, may cause pain, may involve extraction of teeth and suturing of gums and usually requires the animal to remain completely still for a minimum of 30 minutes to as long as 2 -3 hours depending upon the extent of dental disease. Dental cleanings are broken down into the different steps described below:

- 1) **Examination/Probing/Scaling:** The process starts with oral examination, probing of tooth pockets and scaling of teeth. Teeth and gums are examined for pockets above and below the gum line, for caries (cavities), missing teeth, loose teeth, fractured teeth, gum recession and resorptive lesions. Scaling is performed with an ultrasonic scaler to remove tartar above and below the gum line. Arlington Animal Hospital utilizes a high quality modern scaler that uses air to produce vibrations and is less damaging to teeth.
 - 2) **Extractions/Suturing:** Teeth that are loose, have excessive gum recession, are fractured or have root damage are extracted and their pockets sutured as required. Radiographs are vitally important as they can show teeth that appear to be normal above the gum line but have infected roots below the gum line. Extraction of teeth can be a difficult process and may require use of high speed drills, gum flaps and lip flaps. Many teeth require cutting with a high speed drill to be removed and extractions have to be done carefully to prevent fractures of the jaw and damage to other teeth.
 - 3) **Polishing:** Minor tooth surface defects are smoothed out with pumice utilizing a low speed polishing unit. This helps make the tooth surface resistant to plaque formation and adherence. Each surface of each tooth must be polished.
 - 4) **Irrigation:** A pressurized spray is utilized to remove small amounts of tartar, plaque, left over pumice and bacteria from the tooth surfaces, gums and between the teeth.
 - 5) **Fluoride Treatment:** The surface of the teeth are coated in fluoride and allowed to sit for at least four minutes. This decreases tooth sensitivity, strengthens enamel and decreases the rate of future plaque formation.
-

HOME CARE IN THE PREVENTION OF DENTAL DISEASE

The goal of home dental care is to remove plaque before it become calcified and adheres to the tooth surface. Home dental care can be divided up into two categories, mechanical management and chemical management.

Mechanical Management:

Tooth Brushing: Tooth brushing is the most effective method of controlling tartar but its use can be highly variable based upon the animal's disposition and the owner's ability. Human toothpaste should not be used due to its unsuitable taste, its detergent composition and its high fluoride content. Animal toothpastes are lactoperoxidase enhanced enzyme products that have antibacterial properties that decrease plaque. Animal toothpaste comes in a variety of flavors and animal toothbrushes vary in size from finger brushes to full size toothbrushes.

Dog Foods and Dental Treats: There are many different prescription and over the counter (OTC) dental foods and dental treats designed to reduce dental plaque and tartar in animals. Hill's Prescription Diet T/D is one of the most effective dental diets and can reduce plaque and tartar formation as much as 60%. This may highly benefit animals that have chronic dental disease.

Dental Toys/Bones: There are many dental toys and bones on the market that help reduce dental plaque and tartar by "scrubbing" the teeth and stimulating the gums. However toys and bones will not replace dental brushing and there is a small risk of gastric obstruction if the animal swallows all or part of the toy or bone. There is also a small risk of tooth fracture with hard toys or bones.

Chemical Management:

Cleansing Gels: Cleansing gels such as Hexarinse and CHX-Guard contain ingredients such as Chlorhexidine that have bacteriostatic and antibacterial effects that can reduce plaque and tartar formation. These gels help reduce plaque but should be used in conjunction with other methods to be truly effective.

CHRONIC DENTAL DISEASE TREATMENT AND MANAGEMENT

Routine Dental Cleanings: Routine dental checks and dental cleanings will minimize spread of bacteria throughout the body and minimize the chances of organ and tissue damage by circulating dental bacteria. Brushing between dental cleanings will promote healthy teeth and gums. Unfortunately there is no substitute for dental cleanings.

Pulse Therapy Antibiotics: Antibiotics can be used as a pre treatment before dental treatment, perioperatively at the time of dental treatment, postoperatively for 7-10 days, and/or in a pulse therapy fashion given the first five to seven days of each month. Pulse therapy antibiotics have been proven to help manage and control chronic dental disease in a variety of cases, especially cases where a dental cleaning may not be feasible.

The key to maintaining good dental health in your animal is consistent dental exams every 6-12 months, routine cleanings, a proper diet and aggressive home dental care.